

LETTER TO THE EDITOR

Individual differences, missing sulci, and nomenclature: A comment on “On presentation of the human cerebral sulci from inside the cerebrum”

Nowinski (2023) proposes a methodology and brain atlas utilizing the inner cortical surface to visualize human cerebral sulci in three dimensions, which allows improved visualization of sulcal relationships. For example, sulci located on the medial portion of the brain can be viewed simultaneously relative to sulci located on the lateral surface of the brain. This is in contrast to most software packages and brain atlases that require separate views of the brain to visualize sulci on the medial and lateral surfaces (Figure 1). Given that sulcal morphology has cognitive and clinical implications (Cachia et al., 2021), this atlas and tool together show promise to have “educational value” as proposed by Nowinski (2023). Nevertheless, in this Letter, we highlight that the present work is also limited in that it (i) overlooks individual differences in cortical folds, (ii) is missing sulci, and (iii) only includes one sulcal nomenclature.

First, in terms of individual differences of cortical folds, prominent sulci that are often depicted as one long, deep structure in atlases can be broken up into variable “complexes” in an individual hemisphere in which this variability is functionally meaningful. Complexes refers to

the fact that annectant gyri, or *pli de passage*, “break up” the sulcus into multiple pieces (Mangin et al., 2019). Often, this morphological variability is related to individual differences in functional brain organization and/or cognitive performance. For example, while the long, deep, and prominent central sulcus (CS) is shown as a single, continuous cortical fold in the present work, it can be separated into as many as five separate segments in a given hemisphere based on the presence of buried gyri (Eichert et al., 2021). This variability across individuals corresponds with variability in functional organization related to motor movement (Germann et al., 2020). The relationship between variability in sulcal morphology and individual differences in functional organization is not specific to the CS but also extends to other sulci: the pre- and post-central (POCS) sulci (Germann & Petrides, 2020; Zlatkina et al., 2016) and superior frontal sulcus (Amiez & Petrides, 2018) are just three additional examples due to space limitations of this Letter (Figure 1a).

Second, if the present atlas is to be used as an educational tool, readers and students should be aware that this example brain is missing

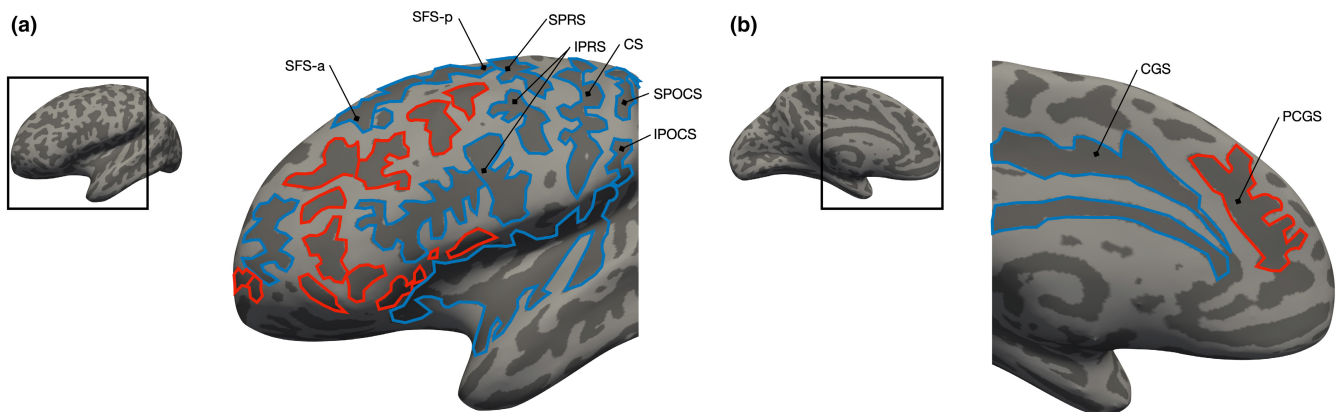


FIGURE 1 Visualizing sulci on the outer (lateral) and inner (medial) surface of the cerebral cortex, but what about missing sulci? (a) Left hemisphere FreeSurfer *inflated* cortical reconstruction (gyri: light gray, sulci: dark gray) from an example Human Connectome Project participant (neuroimaging data from <https://db.humanconnectome.org/>) focused on the lateral prefrontal cortex (LPFC; inset for the location of the zoomed portion). LPFC sulci have been manually defined (outlined) based on the most recent atlas (Petrides, 2019) and published previously in this individual (Miller et al., 2021; Willbrand et al., 2023). Red sulci are those excluded from the present tool, whereas blue sulci are those included. (b) Same format as (a), but for a medial PFC view. Note that two separate views are necessary to visualize sulci on the lateral and medial sides of the cerebral cortex in FreeSurfer, while Nowinski's method allows the visualization of both simultaneously. Nevertheless, as an educational tool, this atlas does not address individual differences in prominent sulci such as the central sulcus (CS), precentral sulcus (PRS), postcentral sulcus (POCS), and superior frontal sulcus (SFS), or the fact that some sulci can be present in one hemisphere and not in another—even in the same individual. For example, only ~70% of hemispheres have a present or prominent paracingulate sulcus (PCGS; red) that is located above the cingulate sulcus (CGS; blue; Amiez et al., 2021).

sulci. That is, not every sulcus is present in every hemisphere. Though many variable sulci excluded in the present work are small and shallow (outlined in Figure 1), which are not the focus of the present work, some are prominent. For example, the paracingulate sulcus (PCGS) is absent in the proposed educational tool/atlas. The PCGS is a prominent longitudinal sulcus parallel to the cingulate sulcus (Figure 1b) that is identifiable in ~70% of hemispheres (Amiez et al., 2021). The presence of the PCGS is cytoarchitecturally, functionally, cognitively, and clinically relevant, as well as is a hominoid-specific structure (Amiez et al., 2021; Amiez & Petrides, 2014; Cachia et al., 2021).

Third, it is important for readers of the journal who may be unfamiliar with brain anatomy and students who may use this atlas to be aware that there are many names for the same sulcus or gyrus. This issue stems all the way back to one of the first atlases to begin to collate the many names proposed by different anatomists (Ecker, 1869) and is an issue that continues to the present day (Ten et al., 2018; Weiner & Zilles, 2016; Willbrand & Parker, 2022). One such example is the “superior occipital sulcus” labeled in the present work that is now commonly referred to as the paroccipital sulcus (Petrides, 2019), which was labeled as such by Wilder (1886).

Of course, the three issues raised in this Letter are not only relevant for providing the most accurate research tools for educating future neuroanatomists, but also for future neurosurgeons as sulci are used as “corridors,” or entry points, in neurosurgery (Ribas et al., 2006; Tomaiuolo & Giordano, 2016). Finally, these three issues are not limited to the present work and reflect ongoing issues in the broader neuroanatomical field that require further discussions among neuroanatomists moving forward.

ACKNOWLEDGMENTS

This letter was supported by NSF CAREER Award 2042251.

CONFLICT OF INTEREST STATEMENT

The authors declare no competing financial interests.

Ethan H. Willbrand^{1,2,3} 

Benjamin J. Parker¹

Kevin S. Weiner^{1,2}

¹Helen Wills Neuroscience Institute, University of California, Berkeley, Berkeley, California, USA

²Department of Psychology, University of California, Berkeley, Berkeley, California, USA

³Medical Scientist Training Program, University of Wisconsin-Madison, Madison, Wisconsin, USA

Correspondence

Kevin S. Weiner, Helen Wills Neuroscience Institute, University of California, Berkeley, CA, USA.

Email: kweiner@berkeley.edu

ORCID

Ethan H. Willbrand  <https://orcid.org/0000-0003-4625-5642>

REFERENCES

- Amiez, C. & Petrides, M. (2014) Neuroimaging evidence of the anatomofunctional organization of the human cingulate motor areas. *Cerebral Cortex*, 24(3), 563–578. Available from: <https://doi.org/10.1093/cercor/bhs329>
- Amiez, C. & Petrides, M. (2018) Functional rostro-caudal gradient in the human posterior lateral frontal cortex. *Brain Structure & Function*, 223(3), 1487–1499. Available from: <https://doi.org/10.1007/s00429-017-1567-z>
- Amiez, C., Sallet, J., Novek, J., Hadj-Bouziane, F., Giacometti, C., Andersson, J. et al. (2021) Chimpanzee histology and functional brain imaging show that the paracingulate sulcus is not human-specific. *Communications Biology*, 4(1), 54. Available from: <https://doi.org/10.1038/s42003-020-01571-3>
- Cachia, A., Borst, G., Jardri, R., Raznahan, A., Murray, G.K., Mangin, J.F. et al. (2021) Towards deciphering the fetal Foundation of normal cognition and cognitive symptoms from sulcation of the cortex. *Frontiers in Neuroanatomy*, 15, 712862. Available from: <https://doi.org/10.3389/fnana.2021.712862>
- Ecker, A. (1869) *Die hirnwindungen des menschen*. Braunschweig: Friedrich Vieweg & Sohn.
- Eichert, N., Watkins, K.E., Mars, R.B. & Petrides, M. (2021) Morphological and functional variability in central and subcentral motor cortex of the human brain. *Brain Structure & Function*, 226(1), 263–279. Available from: <https://doi.org/10.1007/s00429-020-02180-w>
- Germann, J., Chakravarty, M.M., Collins, D.L. & Petrides, M. (2020) Tight coupling between morphological features of the central sulcus and somatomotor body representations: a combined anatomical and functional MRI study. *Cerebral Cortex*, 30(3), 1843–1854. Available from: <https://doi.org/10.1093/cercor/bhz208>
- Germann, J. & Petrides, M. (2020) Area 8A within the posterior middle frontal gyrus underlies cognitive selection between competing visual targets. *eNeuro*, 7(5), ENEURO.0102-20.2020. Available from: <https://doi.org/10.1523/ENEURO.0102-20.2020>
- Mangin, J.-F., le Guen, Y., Labra, N., Grigis, A., Frouin, V., Guevara, M. et al. (2019) “Plis de passage” deserve a role in models of the cortical folding process. *Brain Topography*, 32(6), 1035–1048. Available from: <https://doi.org/10.1007/s10548-019-00734-8>
- Miller, J.A., Voorhies, W.I., Lurie, D.J., D'Esposito, M. & Weiner, K.S. (2021) Overlooked tertiary sulci serve as a meso-scale link between microstructural and functional properties of human lateral prefrontal cortex. *The Journal of Neuroscience: The Official Journal of the Society for Neuroscience*, 41(10), 2229–2244. Available from: <https://doi.org/10.1523/JNEUROSCI.2362-20.2021>
- Nowinski, W.L. (2023) On presentation of the human cerebral sulci from inside of the cerebrum. *Journal of Anatomy*, 1–7. Available from: <https://doi.org/10.1111/joa.13880>
- Petrides, M. (2019) *Atlas of the morphology of the human cerebral cortex on the average MNI brain*. London: Elsevier.
- Ribas, G.C., Yasuda, A., Ribas, E.C., Nishikuni, K. & Rodrigues, A.J., Jr. (2006) Surgical anatomy of microneurosurgical sulcal key points. *Neurosurgery*, 59(4 Suppl 2), ONS177–ONS210. Available from: <https://doi.org/10.1227/01.NEU.0000240682.28616.b2>
- Ten Donkelaar, H.J.T., Tzourio-Mazoyer, N. & Mai, J.K. (2018) Toward a common terminology for the gyri and sulci of the human cerebral cortex. *Frontiers in Neuroanatomy*, 12, 93. Available from: <https://doi.org/10.3389/fnana.2018.00093>
- Tomaiuolo, F. & Giordano, F. (2016) Cerebral sulci and gyri are intrinsic landmarks for brain navigation in individual subjects: an instrument to assist neurosurgeons in preserving cognitive function in brain tumour surgery (commentary on Zlatkina et al.). *The European Journal of Neuroscience*, 43, 1266–1267. Available from: <https://doi.org/10.1111/ejn.13072>
- Weiner, K.S. & Zilles, K. (2016) The anatomical and functional specialization of the fusiform gyrus. *Neuropsychologia*, 83, 48–62. Available from: <https://doi.org/10.1016/j.neuropsychologia.2015.06.033>

- Wilder, B.G. (1886) Human cerebral fissures: their relations and names and the methods of studying them. *American Naturalist*, XX, 901-902.
- Willbrand, E.H., Ferrer, E., Bunge, S.A. & Weiner, K.S. (2023) Development of human lateral prefrontal sulcal morphology and its relation to reasoning performance. *The Journal of Neuroscience: the Official Journal of the Society for Neuroscience*, 43(14), 2552-2567. Available from: <https://doi.org/10.1523/JNEUROSCI.1745-22.2023>
- Willbrand, E.H., Parker, B.J., Voorhies, W.I., Miller, J.A., Lyu, I., Hallock, T. et al. (2022) Uncovering a tripartite landmark in posterior cingulate cortex. *Science Advances*, 8(36), eabn9516. Available from: <https://doi.org/10.1126/sciadv.abn9516>
- Zlatkina, V., Amiez, C. & Petrides, M. (2016) The postcentral sulcal complex and the transverse postcentral sulcus and their relation to sensorimotor functional organization. *The European Journal Of Neuroscience*, 43(10), 1268-1283. Available from: <https://doi.org/10.1111/ejn.13049>